

# X- Boven de clavicula

Peter R.E.J.W. Kraal, Radioloog



1. X- Schedel
2. X- Os nasale
3. X- Sinus
4. X- Orbita



1. X- Schedel

2. X- Os nasale

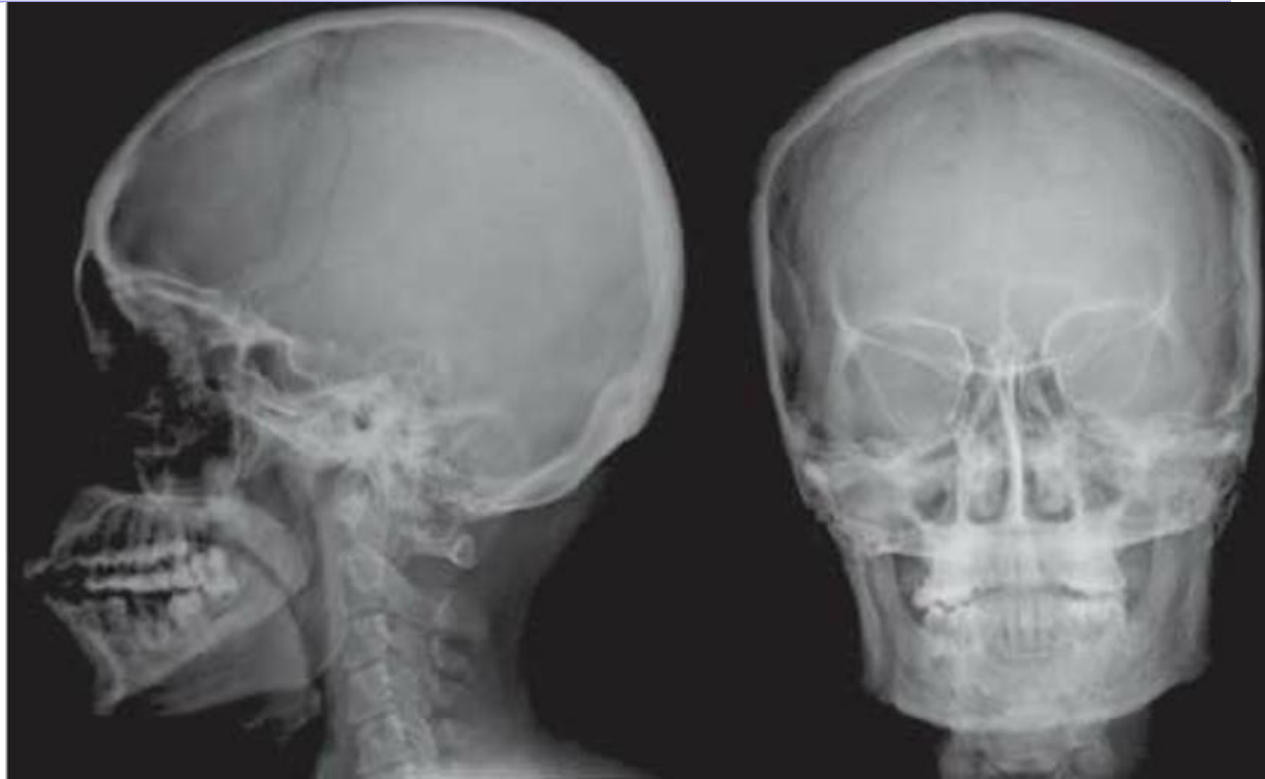3. X- Sinus

4. X- Orbita

# X schedel

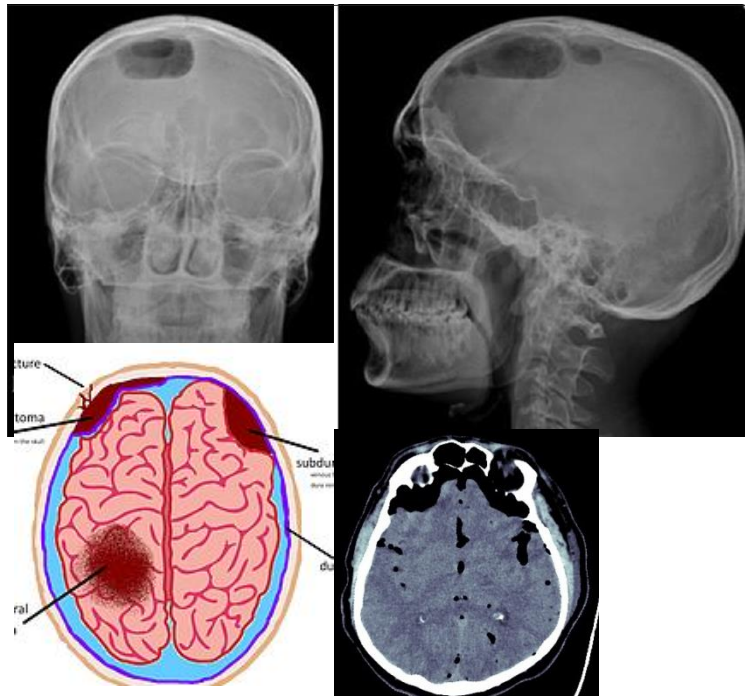
## Wat wil je eigenlijk zien?

- >20% fractures mis je
- Weke delen afwijkingen mis je
- intracraniele afwijkingen mis je
  - Behalve pneumocefalie

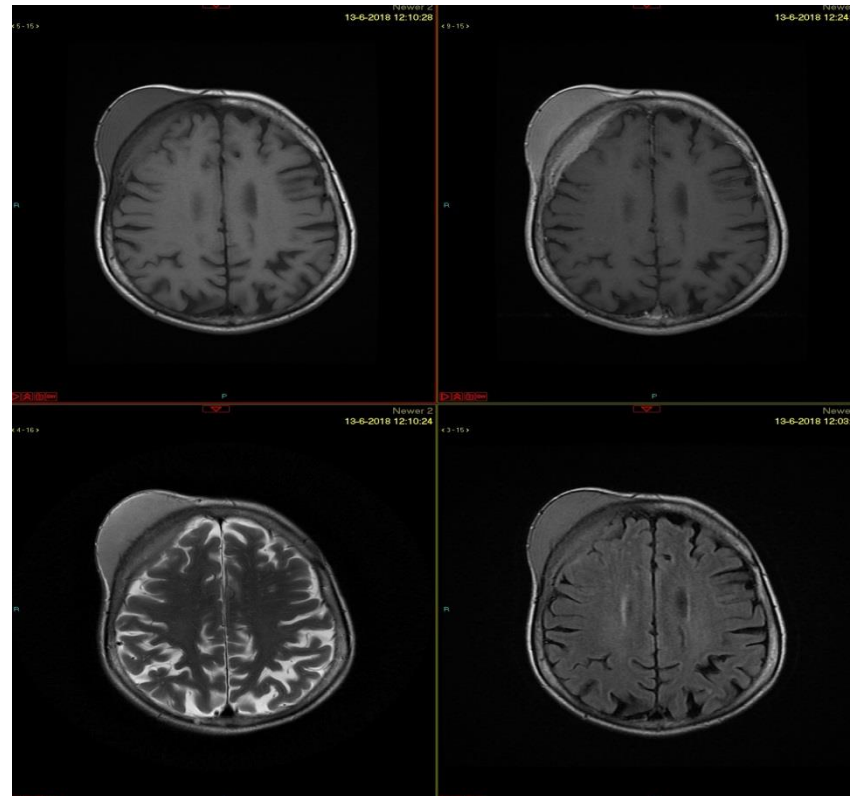
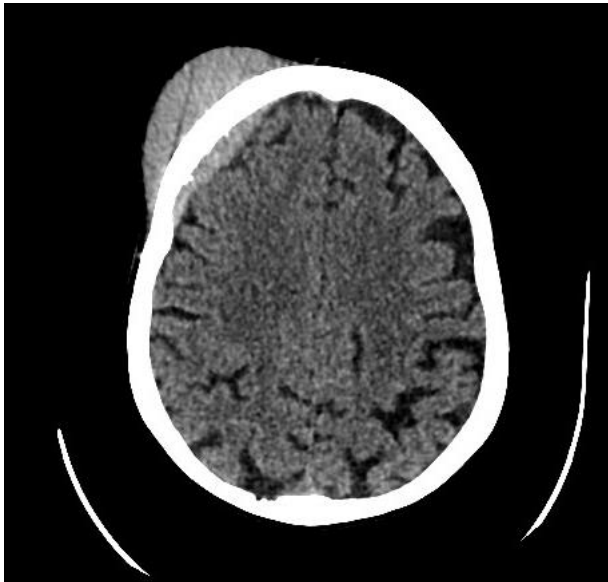
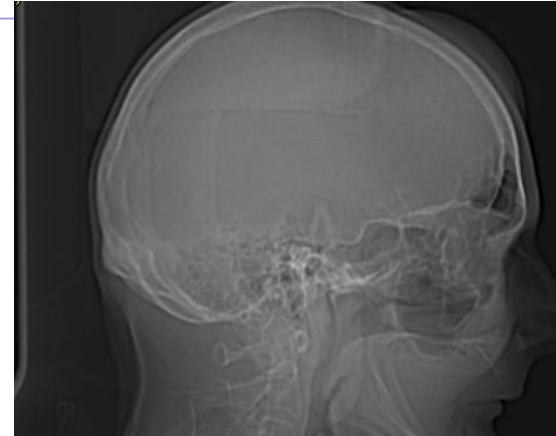
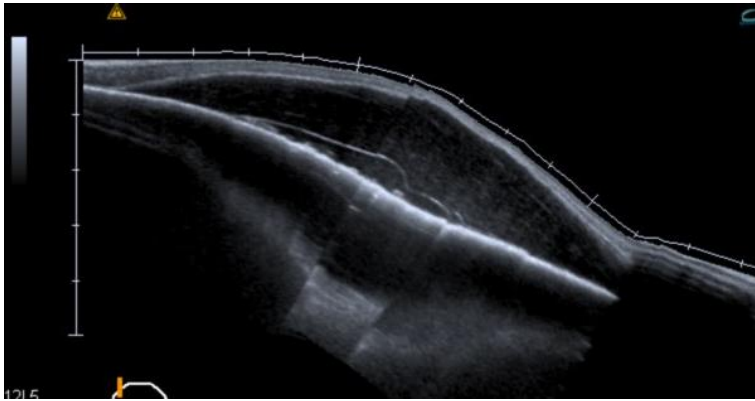


Geen X-schedel

Wel Echo en eventueel CT – schedel of...



# X schedel



1. X- Schedel

2. X- Os nasale

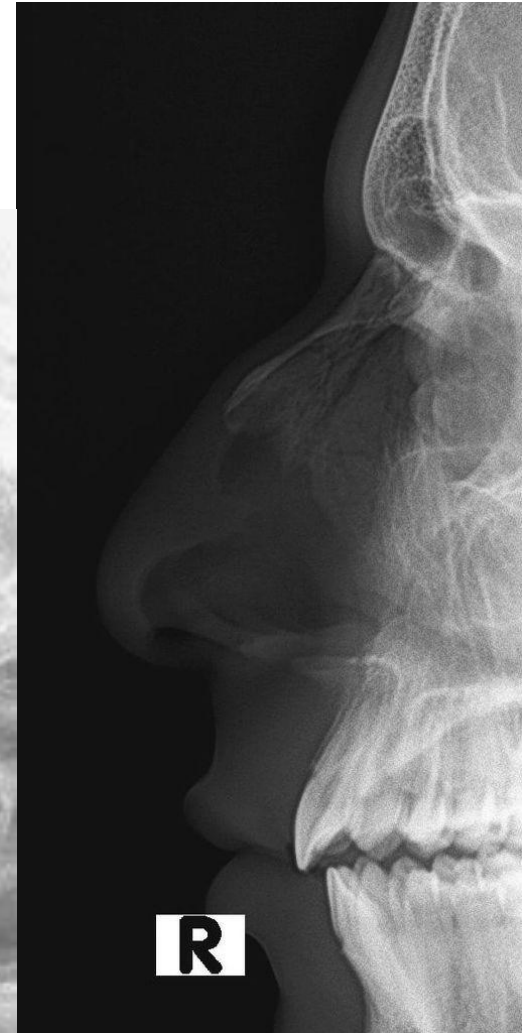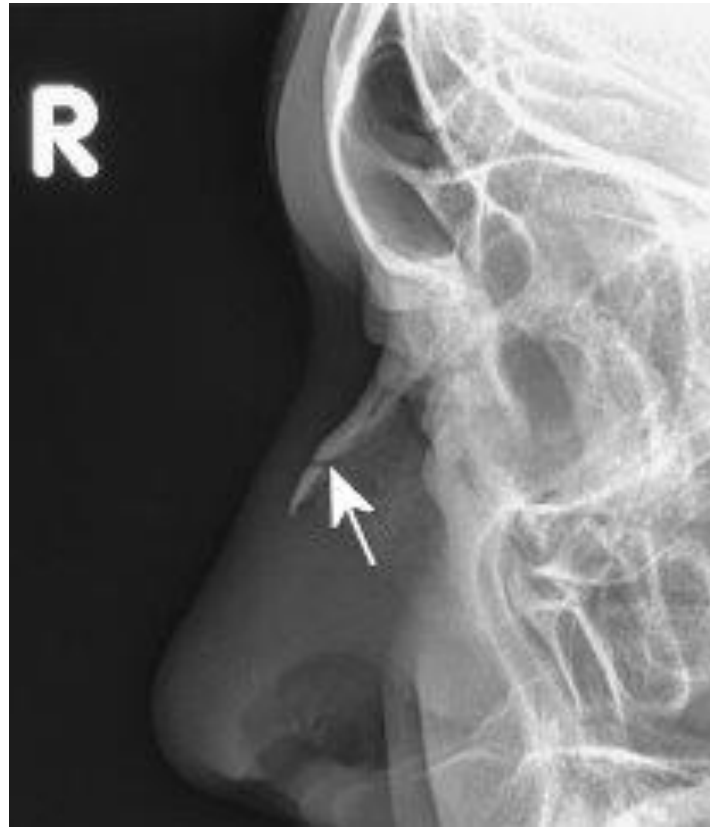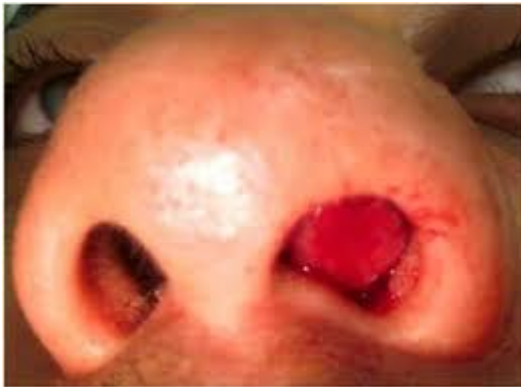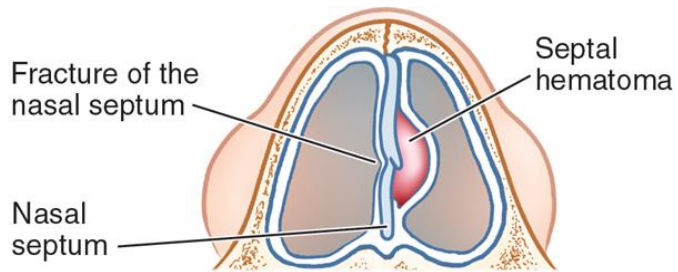
3. X- Sinus

4. X- Orbita

# X os nasale

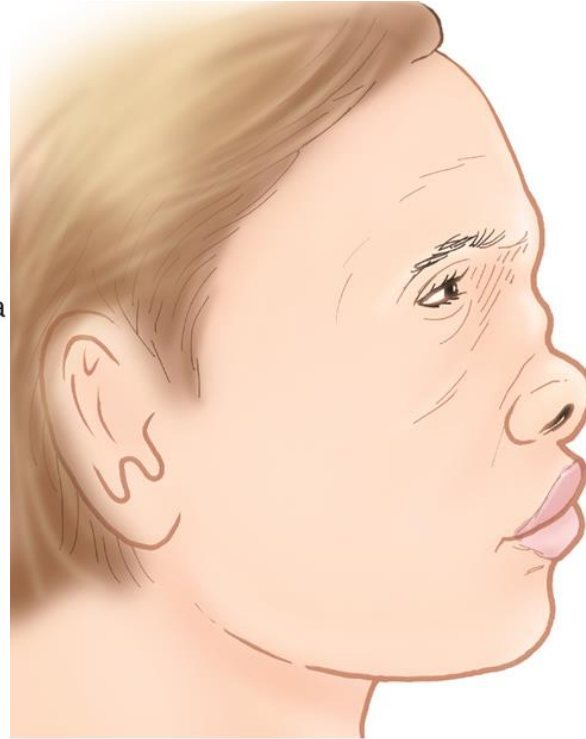
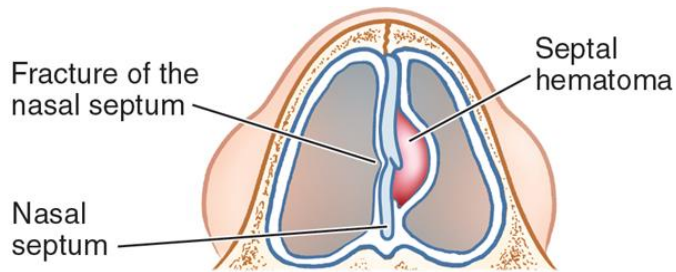
## Wat wil je eigenlijk zien? ... complicaties

- Scheefstand
- Septum hematoom



## Wat wil je eigenlijk zien? ... complicaties

- Scheefstand
- Septum hematoom



Geen X-nasale



Source: Reichman EF: *Emergency Medicine Procedures*,  
Second Edition: [www.accessemergencymedicine.com](http://www.accessemergencymedicine.com)  
Copyright © The McGraw-Hill Companies, Inc. All rights reserved.





1. X- Schedel

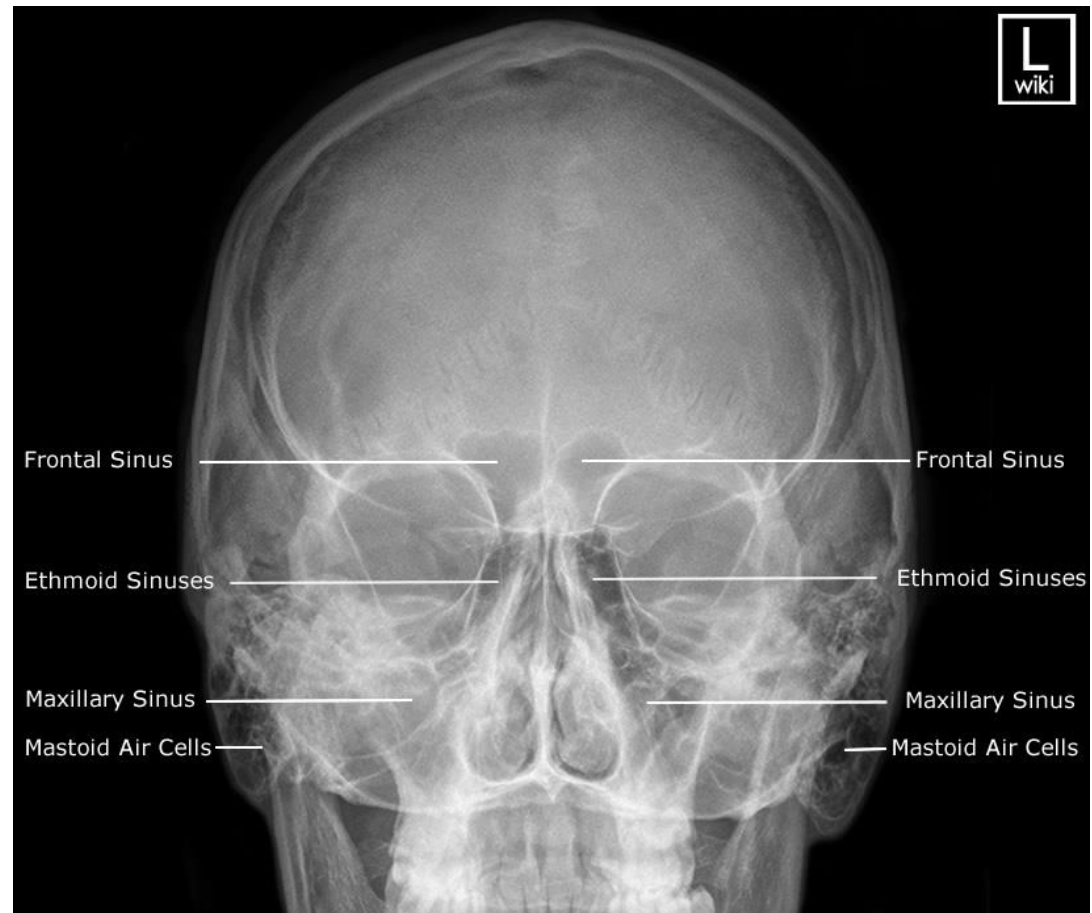
2. X- Os nasale

3. X- Sinus

4. X- Orbita

# X sinus

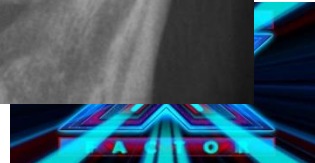
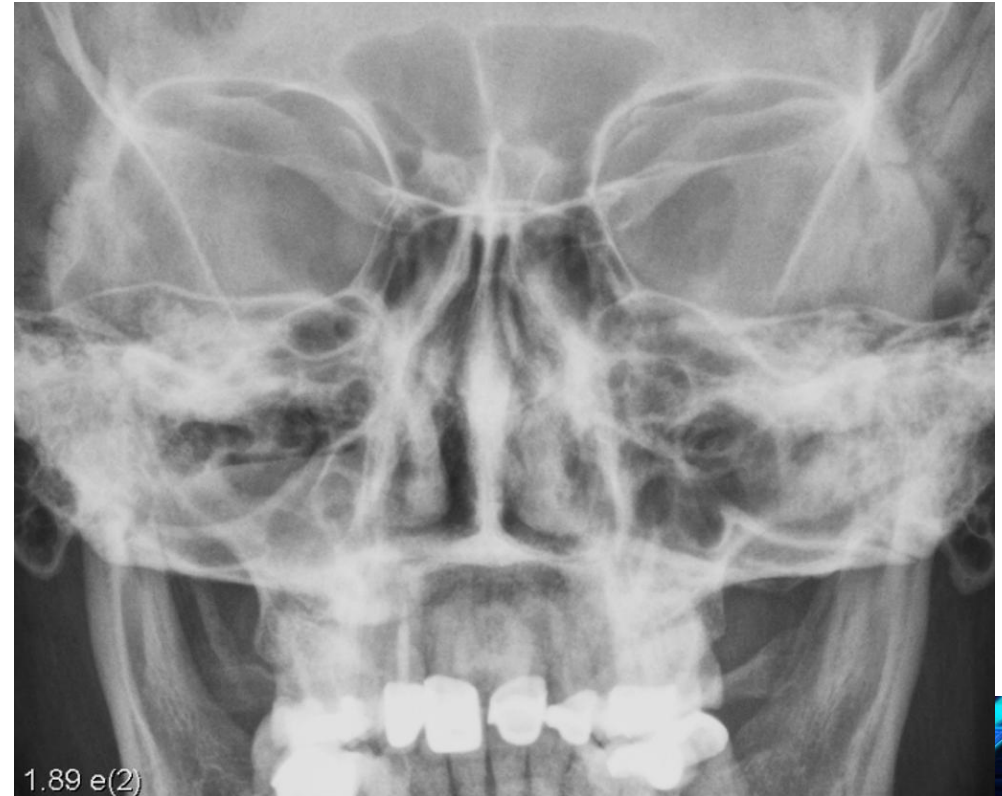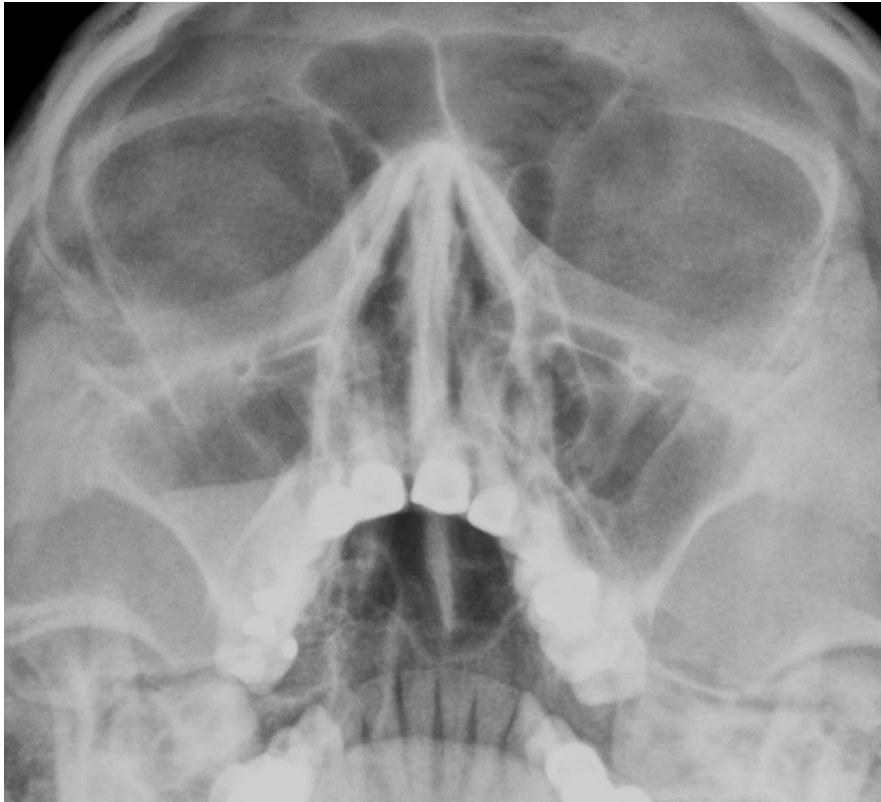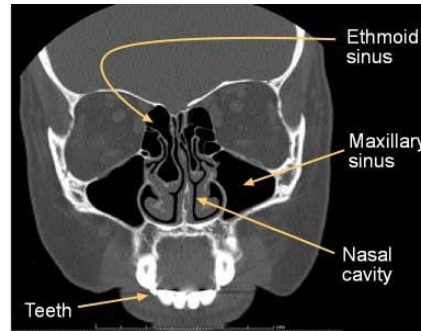
- **NHG Acute Rhinosinusitis**
  - Geen X-sinus
- **Richtlijn Chronische rinosinusitis**
  - Geen X-sinus
  - CT-Sinus



# X sinus

## Wat wil je eigenlijk zien?

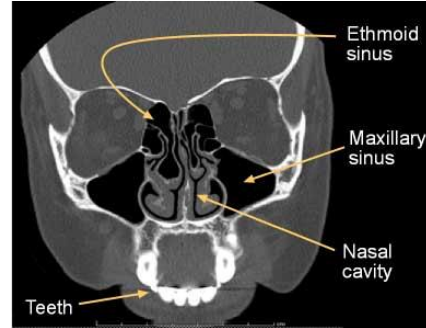
- Sensitiviteit  $\ll$  CT



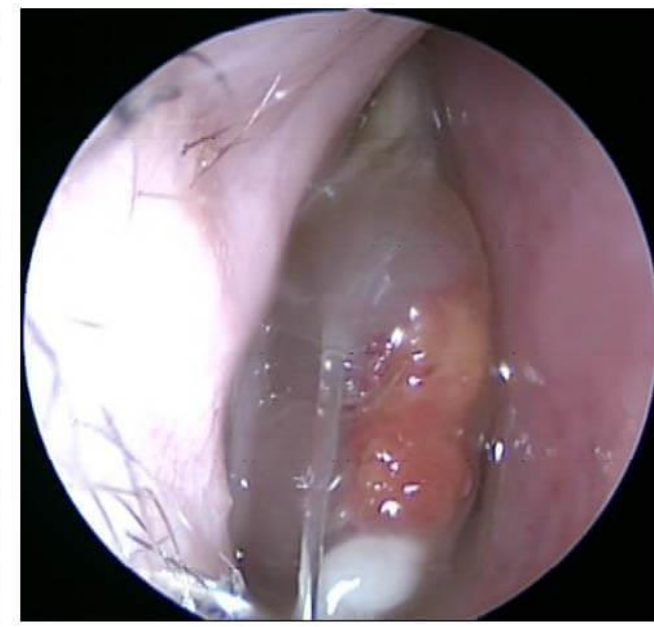
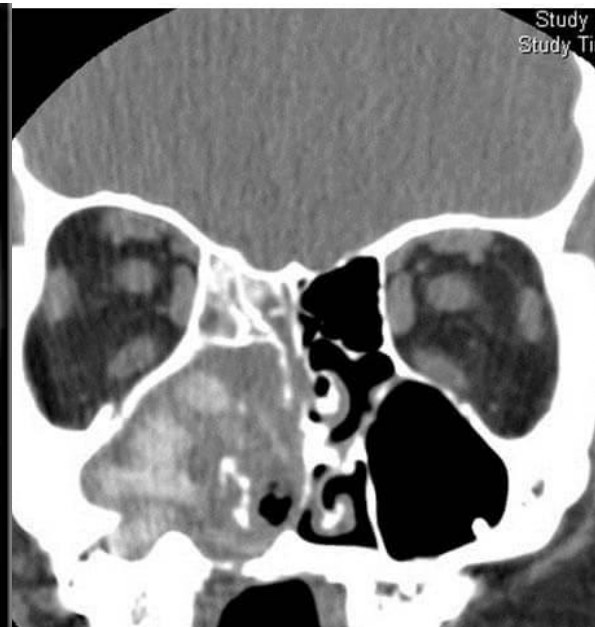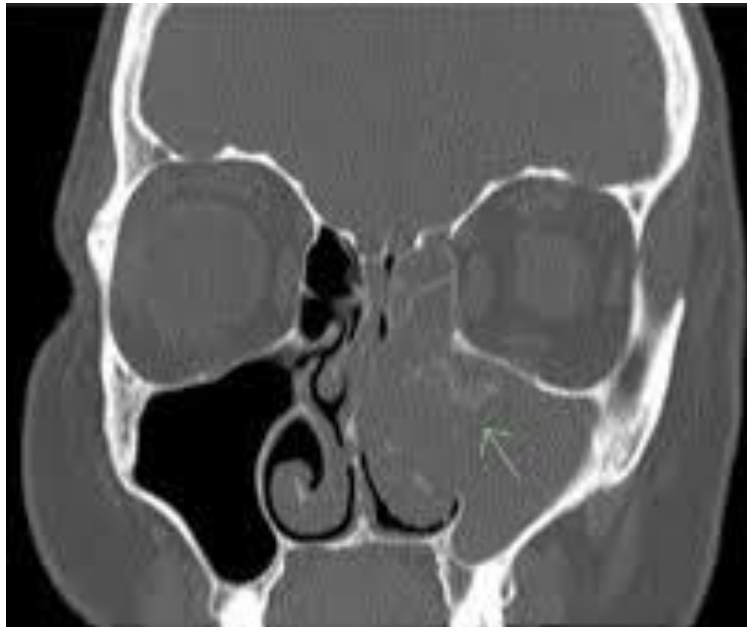# X sinus

## Wat wil je eigenlijk zien?

- Sluiering
- Alternatieve diagnose
  - Funguale sinusitis (dens)
  - RIP (geinverteerd papilloom)



Geen X-sinus  
CT-sinus alleen op indicatie



1. X- Schedel

2. X- Os nasale

3. X- Sinus

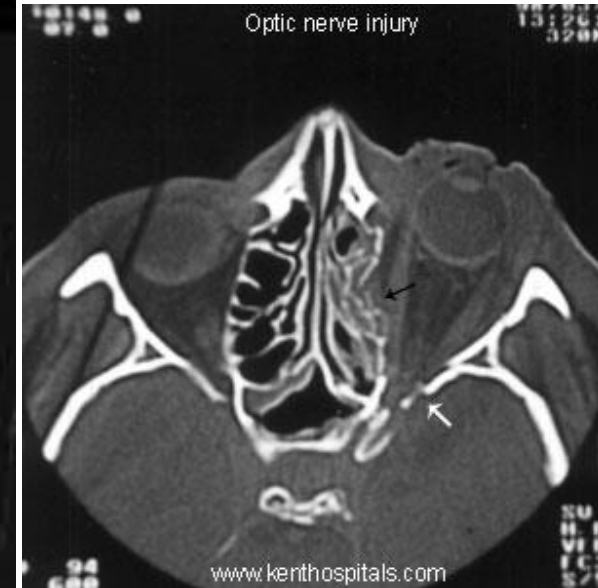
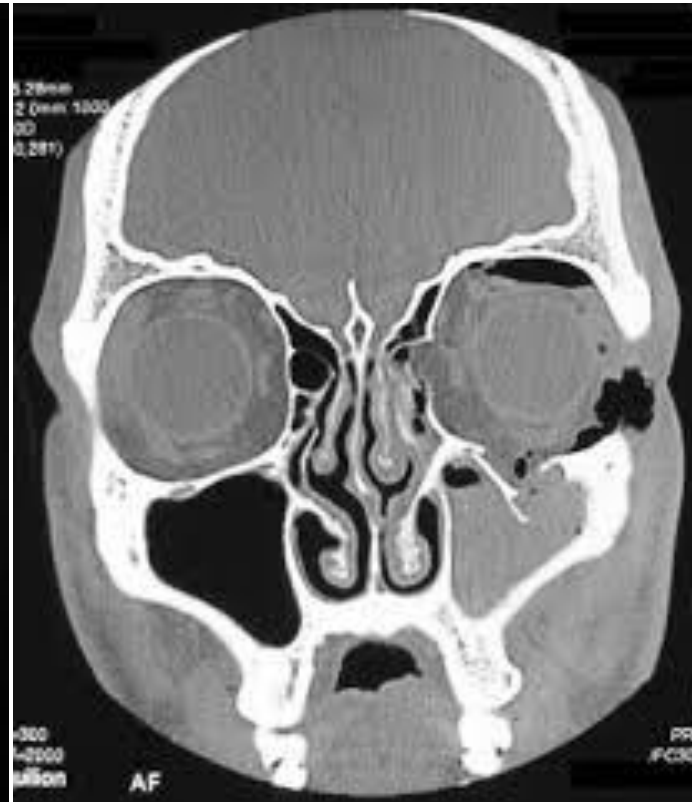
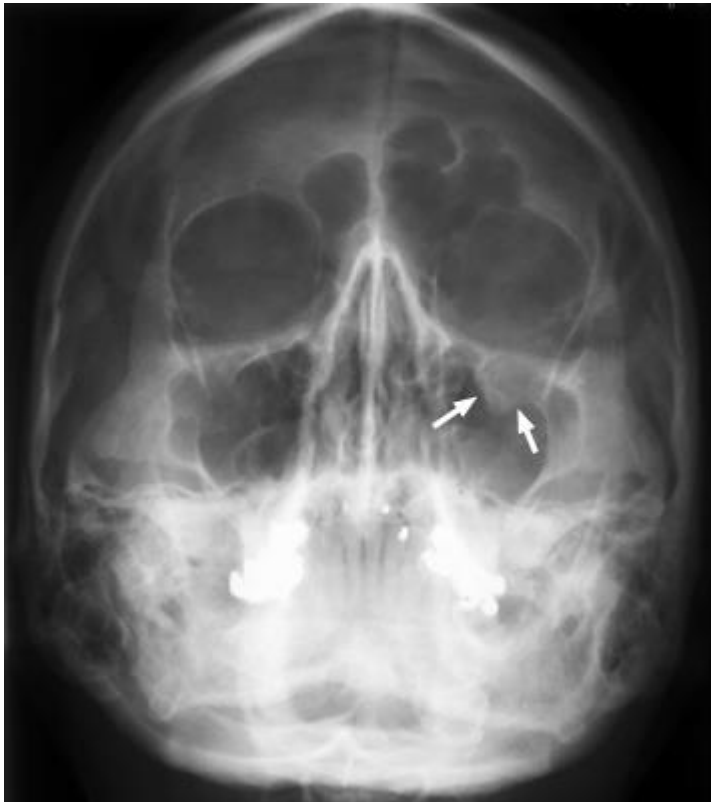4. X- Orbita

# X orbita

## Wat wil je eigenlijk zien?

- Hele orbita (dus CT)
- Weke delen (oogspieren, nervus)
- Lucht, bloeding, ...

Geen X-orbita  
Wel CT-aangezicht



Bedankt voor de aandacht!

